
ORIGINAL ARTICLE**Comparative Evaluation of Dexmedetomidine versus Clonidine as an Adjuvant in Supraclavicular Brachial Plexus Block***Roona Singh¹, Amol Singam^{1*}**¹Department of Anaesthesiology, Acharya Vinoba Bhave Rural Hospital, Jawaharlal Nehru Medical College, Sawangi (Meghe), Wardha- 442001(Maharashtra) India*

Abstract

Background: Supraclavicular block is considered to be the ideal block for upper extremity surgeries as it provides ideal operative conditions by complete muscle relaxation and stable intra operative hemodynamics. *Aim and Objectives:* The aim of the study was to evaluate the efficacy and safety of Clonidine and Dexmedetomidine as an adjuvant to Ropivacaine in supraclavicular brachial plexus block. *Material and Methods:* Ninety patients were divided randomly into 3 groups of 30 each. Group CL: Patients received injection Ropivacaine 0.5% (30 ml) + normal saline (1 ml), Group CD: Patients received injection Ropivacaine 0.5% (30 ml) + injection Clonidine (150 µg), Group DX: Patients received injection Ropivacaine 0.5% (30 ml) + injection Dexmedetomidine (100 µg). Onset of sensory and motor block, duration of analgesia and motor block, complications and side effects of the study drugs were compared among the three groups. *Results:* The onset of sensory and motor block was earliest in Group DX, followed by Group CD, followed by Group CL. Complete sensory and motor block were earliest in Group DX, followed by Group CD, followed by Group CL. Similarly duration of sensory and motor block was maximum in Group DX, followed by Group CD, followed by Group CL ($p < 0.05$). *Conclusion:* Dexmedetomidine and Clonidine when added to Ropivacaine for supraclavicular brachial plexus block prolong the duration of analgesia. But Dexmedetomidine is a better adjuvant as compared to Clonidine.

Keywords: Dexmedetomidine, Clonidine, Ropivacaine, Supraclavicular block

Introduction:

Nowadays regional anaesthesia is a preferred technique over general anaesthesia for upper limb surgeries because it helps to avoid the complications and side effects associated with general anaesthesia [1]. Supraclavicular brachial plexus block is known as the “spinal anaesthesia” of upper extremity. The high success rate of the supraclavicular block is attributable to the peculiar anatomical characteristic of the plexus at this level. Here, the plexus is compact hence all the motor, sensory and autonomic nerves are blocked providing complete surgical anaesthesia [2, 3]. Ropivacaine is a new amide type, long acting local anaesthetic with potentially improved safety profile when compared to Bupivacaine. Both its stereo selectivity and its lesser lipophilicity than Bupivacaine contribute to higher threshold for cardiotoxicity and CNS toxicity [4]. The major disadvantage of using only local anaesthetic in regional blocks is that it does not prolong the duration of post operative analgesia [5]. It has been increasing the use of some adjuncts, e.g., opioids, midazolam, ketamine, α -2 adrenoreceptor agonists to local anaesthetic agents to improve the block quality in peripheral nerve blocks. Use of all these drugs is associated with some or other side effects [6]. Of late, both Clonidine and Dexmedetomidine have evidenced a lot of interest as useful additives to local anaesthetic for their

sedative, analgesic, antihypertensive and antiemetic actions [7]. Clonidine is a centrally acting selective partial alpha 2-adrenergic agonist which has been found to extend the duration of action of nerve block when added as an adjuvant to local anaesthetics [8]. Dexmedetomidine is eight times more selective to α_2 receptors than Clonidine [9]. Widespread presence of α_2 receptors in the brain, spinal lamina and peripheral nerves and their role in pain modulation explains the analgesic and local anaesthetic sparing action of these agents [10].

In this study we aimed to compare and evaluate the efficacy of Clonidine 150 μ g and Dexmedetomidine 100 μ g added to 0.5% of Ropivacaine regarding the duration of analgesia as the primary outcome. Secondary outcome measures were onset of sensory block, onset and duration of motor block and side effects associated with both the drugs.

Material and Methods:

The present study was carried out in the Department of Anaesthesiology, Acharya Vinoba Bhave Rural Hospital (AVBRH), affiliated to Jawaharlal Nehru Medical College, Sawangi (M), Wardha, during a period of 3 years. After approval from the institutional ethical committee, 90 patients belonging to American Society of Anaesthetist (ASA) class I and II, aged between 20 to 70 years, weighing between 40 to 70 kg, both male and female posted for various upper limb surgeries excluding shoulder surgeries either elective or emergency under supraclavicular brachial plexus block were included in the study. Exclusion criteria included patients with bony deformity, pregnant females, and obese patients, patients with history of seizures, coagulation

disorders, pneumothorax and unwilling patients. 90 patients were divided randomly into 3 groups of 30 each by computer generated random number table and allocation of the same by sealed envelopes technique.

Group CL (n = 30): Patients received inj. Ropivacaine 0.5% - 30 ml + normal saline - 1ml (total volume 31 ml).

Group CD (n = 30): Patients received inj. Ropivacaine 0.5%-30 ml + Clonidine - 150 μ g (total volume 31 ml).

Group DX (n = 30): Patients received inj. ropivacaine 0.5% - 30 ml + Inj. Dexmedetomidine - 100 μ g (total volume 31 ml)

Pre-anaesthetic check up was done of all the patients. After taking a detailed history thorough general and systemic examination was done to rule out cardiovascular, respiratory or neurological and any associated problems. Weight and routine investigations of the patients were recorded. Informed consent was taken. Local anaesthetic sensitivity test was done. Patients were kept NBM for 8 hours. No pre-medications were given.

On arrival in operation theatre 18 g i.v. cannula was secured in opposite limb and infusion of Ringer's lactate was started at the rate of 80 ml/hr. Standard monitors including non invasive blood pressure, pulse oximetry and ECG were attached to the patient and baseline vital parameters such as pulse rate, systolic and diastolic blood pressure, mean arterial pressure, oxygen saturation and sedation score were recorded.

After appropriate patient positioning, the anaesthetic technique used was subclavian perivascular by using nerve locator. The nerve locator utilized was the Stimuplex DIG (B. Braun,

Allentown, PA). A 22-gauge, 2-inch, short-bevel insulated needle (Stimuplex; B. Braun) was used for the block. Under all aseptic precautions a skin wheal was raised of 1 finger breadth over the lower most palpable portion of the interscalene groove, and the block needle was inserted through it. Then, with the nerve stimulator output was set at 0.9 mA at 1 Hz, the needle was advanced directly caudal until a flexor or extensor response of all the fingers was obtained. At this point the output was reduced to 0.5 to 0.7 mA. If the response was still visible at this level of stimulation, the local anaesthetic solution was injected in 5 ml increments; with repeated aspirations between each increment and the total volume of local anaesthetic solution was injected. The procedure was abandoned if any arterial puncture was noted. The time of administration of drug was noted. Visual and verbal contact with the patient was maintained during and after the injection.

Two min after giving the block, sensory block assessment was done at each minute over 4 major nerve distribution areas (radial, ulnar, median and musculocutaneous) on a three point scale (0 – normal sensation; 1- blunt sensation; 2 – no sensation) and motor block was evaluated with Modified Bromage Scale (MBS; 0- Normal muscle function, 1- Elbow flexion; 2- Wrist flexion; 3- Full motor block)

Onset of sensory block: Time from the end of injection of the study drug to pinprick test score of 1.

Onset of motor block: Time from the end of the injection of study drug to appearance of MBS grade I.

Complete sensory block: Time from the end of injection of study drug to pinprick test score of 2.

Complete motor block: Time from the end of injection of study drug to appearance of MBS grade 3.

Duration of surgery: The duration between the first skin incision and complete closure was the duration of surgery.

Duration of motor block: Time between complete motor block and full arm mobility (MBS 0) was the time taken as duration of motor block.

Total duration of analgesia: This was the time taken from complete sensory block and first injection of systemic analgesic.

Patients were assessed for duration of analgesia as per Visual Analogue Scale (VAS) of 0 to 10 where 0 represents no pain and 10 represents worst possible pain. The VAS was recorded immediately in the post-operative period and every 2 hourly for the next 12 hours and this was taken as the end of our study. The rescue analgesia was given in the form of inj. diclofenac sodium (1.5 mg/kg) intramuscularly at the VAS \geq 4.

All the side effects and complications related to the technique and the drugs were evaluated and treated accordingly. Patients requiring supplemental anaesthesia were excluded from the study.

Statistical Analysis:

A study power 80% and alpha level of 0.05 sample size was calculated for the 3 groups. Aimed sample size was 90 patients with 30 patients in each group. Statistical analysis was done by using descriptive and inferential statistics using Chi square test, student's unpaired t test, one way ANOVA and Multiple Comparison Tukey test and the software used in the analysis was SPSS 22.0 version and Graph Pad Prism 6.0 version and $p < 0.05$ is considered as level of significance.

Results:

Table 1 shows the patients were comparable with respect to age, gender, weight, ASA class and duration of surgery. Table 2 shows the patients were comparable with respect to the type of surgery done. Table 3 shows that onset of sensory block was earliest in Dexmedetomidine Group 2.5 ± 0.73 min, followed by Clonidine Group 3.1 ± 0.54 min, followed by Ropivacaine alone Group 3.93 ± 0.98 min. Similarly complete sensory block was achieved fastest in Dexmedetomidine Group followed by Clonidine Group followed by Ropivacaine alone Group.

Onset of motor block was comparable in DX and CD groups, which was significantly earlier when

compared to Ropivacaine alone Group. The mean time to achieve complete motor block in DX Group was 18.66 ± 1.51 min, followed by 20.03 ± 2.22 min in CD Group followed by 26.88 ± 4.43 min in CL Group. The difference was highly significant across the groups as indicated by p value < 0.05 . Duration of motor block was maximum in group DX followed by group CD and group CL. The difference was significant across the groups. Duration of analgesia was maximum in DX Group i.e. 701.5 ± 35 min, followed by CD Group 472.7 ± 28.67 min, followed by CL Group 410.56 ± 25.4 min, difference was significant across the groups.

Table 1: Demographic Data

Patient Characteristics	Group CL	Group CD	Group DX	P-value
Age (years)	42.10±15.12	43.86±14.20	42.40±13.14	p=1.00 ^{NS}
Gender (male/female)	18/12	17/13	17/13	p=0.95 ^{NS}
ASA(I/II)	22/8	23/7	23/7	p=0.94 ^{NS}
Weight (kilograms)	52.46±9.31	51.03±8.39	53.33±8.21	p=0.60 ^{NS}
Duration of surgery(min)	69.40±10.87	71.33±12.43	70.83±13.67	p=0.97 ^{NS}

NS – not significant

Table 2: Distribution of Patients According to Type of Surgery

Type of surgery	Group CL	Group CD	Group DX	P value
Debridement and primary suturing	4 (13.3%)	3 (10%)	5 (16.7%)	F = 2.51 p=0.99 ^{NS}
Nailing SOS plating	5 (16.7%)	6 (20%)	4 (13.3%)	
Percutaneous K Wire Fixation in Colles#	6 (20%)	8 (26.7%)	7 (23.3%)	
OR & Plate Osteosynthesis (ORPS)	7 (23.3%)	5 (16.7%)	6 (20%)	
OR and IF (ORIF)	5 (16.7%)	4 (13.3%)	3 (10%)	
Implant Removal (IR)	3 (10%)	4 (13.3%)	5 (16.7%)	
Total	30 (100%)	30 (100%)	30 (100%)	

NS – not significant

Table 3: Onset of Sensory and Motor Block, Duration of Motor Block, Duration of Analgesia

Parameters	Group CL	Group CD	Group DX
Onset of sensory block (min)	3.93±0.98	3.1±0.54	2.5±0.73
Onset of motor block	11.06±2.53	8.30±4.86	6.56±0.971
Complete sensory block (min)	20.73±3.34	16.70±2.0	14.06±1.25
Complete motor block (min)	26.83±3.25	20.30±2.21	18.66±1.51
Duration of motor block (min)	349.43±39.99	408.86±42.63	559.7±18.69
Duration of analgesia VAS > 4	410.56±25.4	472.7±28.67	701.5±35

p-value comparison	Group CL and CD	Group CL and DX	Group CD and DX
Onset of sensory block	0.0001*	0.0001*	0.01*
Onset of motor block	0.008*	0.0001*	0.063 ^{NS}
Complete sensory block	0.0001*	0.0001*	0.001*
Complete motor block	0.0001*	0.0001*	0.03*
Duration of sensory block	0.0001*	0.0001*	0.0001*
Duration of analgesia (VAS >4)	0.0001*	0.0001*	0.0001*

NS – not significant, * significant

In figure 1, we can see a statistically significant fall in pulse rate in group DX and group CD from 10 min till 90 min intra-operatively and from 2 hrs to 4 hrs post operatively as compared to Group CL. But Group CD and Group DX were comparable with each other in this regard. In Graph 2, it is evident that 10 min after giving the block till 240 min there was a significant fall in mean MAP in Group DX and Group CD as compared to Group CL. The respiratory rate was comparable among the groups throughout the study period. Figure 3 shows that patients

belonging to Group DX were having significantly more sedation compared to patients in CD Group from 15 min till 240 min after giving the block. Table 4 shows, technique related complications, two patients in group CL, 1 patient in DX groups, while 1 in CD group had pneumothorax. Horner's syndrome was observed in 1 patient in CD group and 1 patient in CL group and 2 patients in DX group. Haematoma was not observed in any of the groups. Pneumothorax and Horner's syndrome were observed in all the three groups, the difference was statistically insignificant.

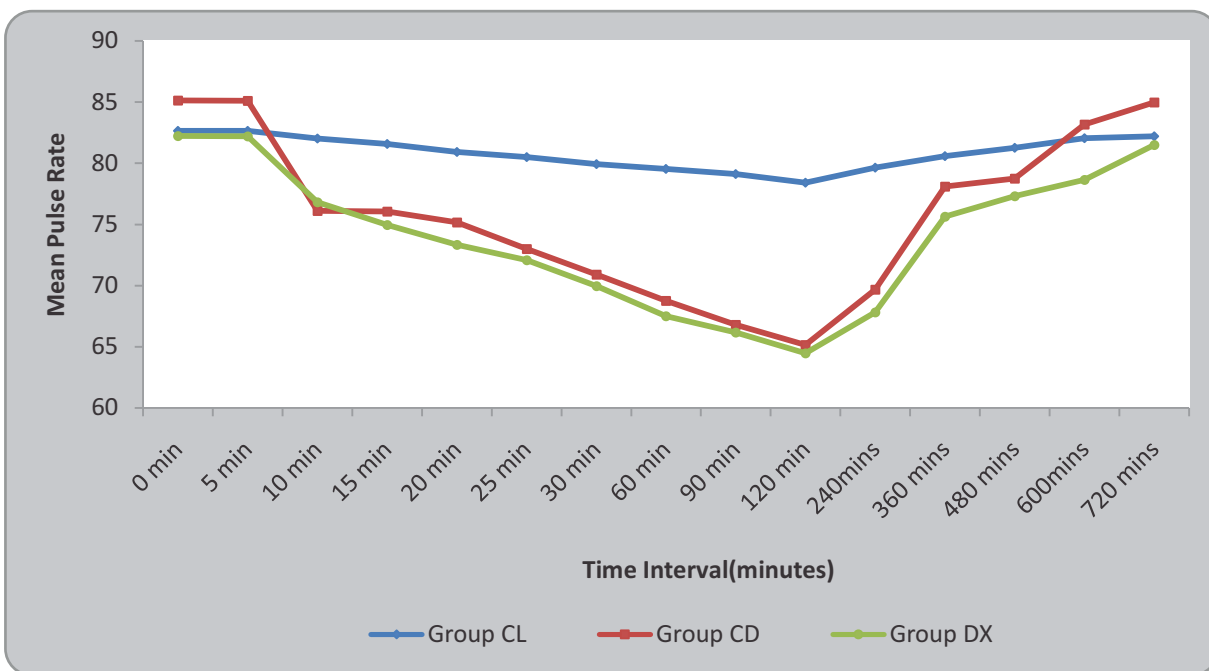


Fig. 1: Mean Pulse Rate at Different Time Points in the Three Groups

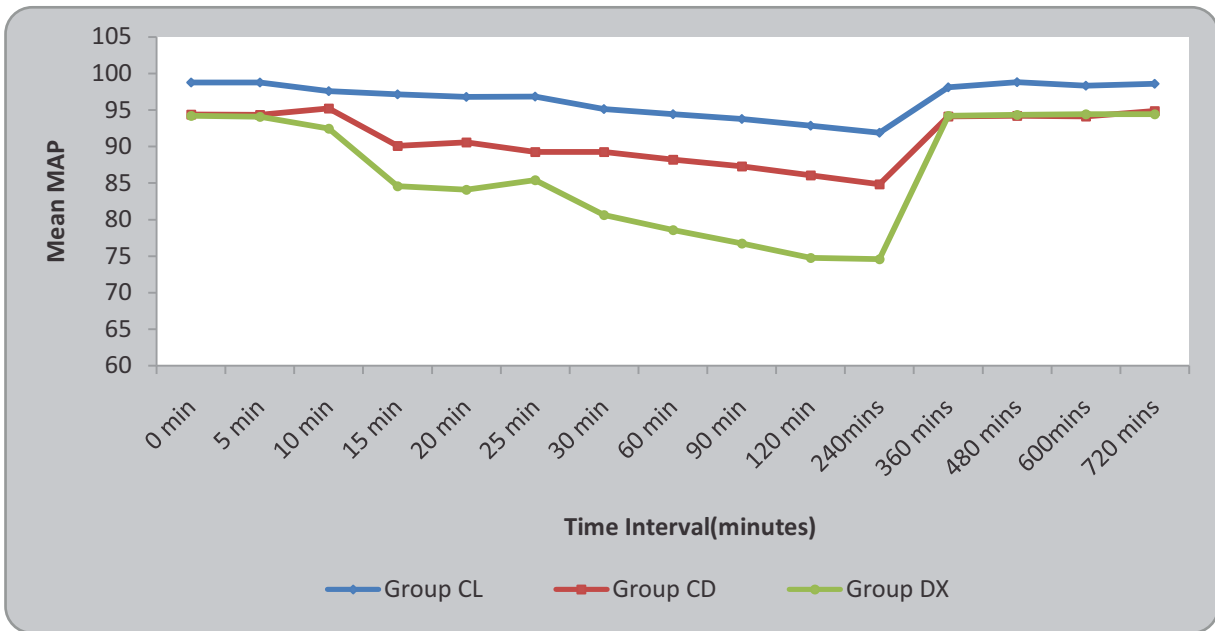


Fig. 2: Mean Arterial Pressure at Different Time Points in the Three Groups

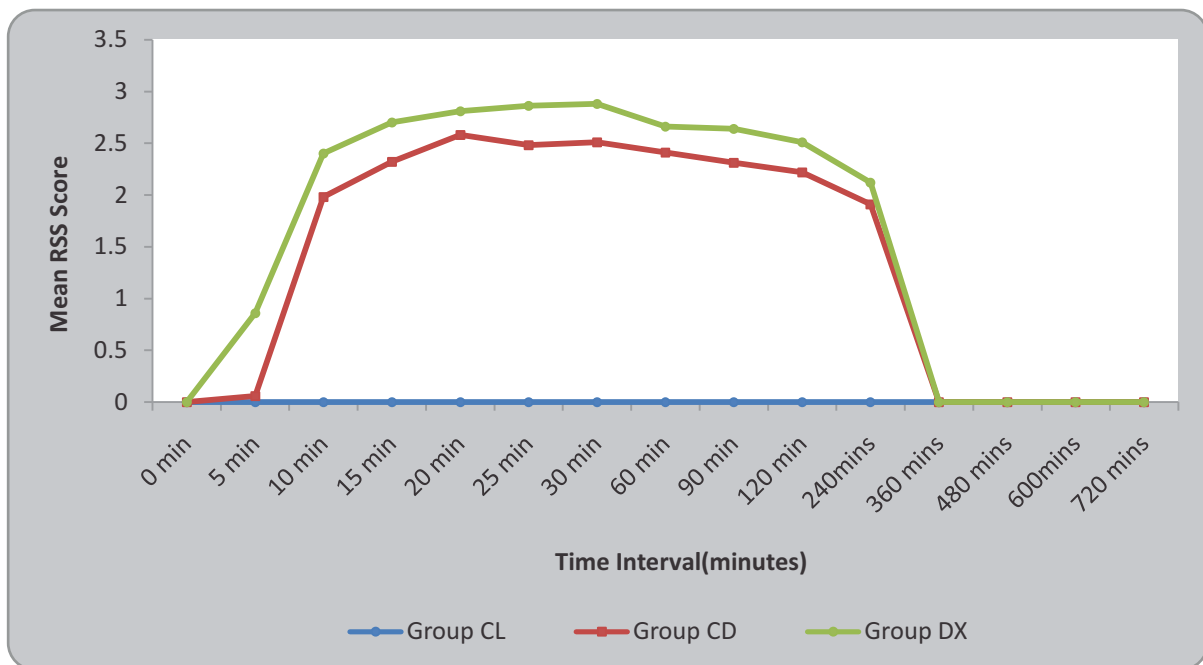


Fig. 3: Distribution of Patients According to Ramsay Sedation Score at Different Time Points during the Study Period

Table 4: Complications Related to Supraclavicular Block

Complications	Group CL	Group CD	Group DX	p-value
Pneumothorax	2(6.66%)	1(3.33%)	1(3.33%)	$\chi^2 = 2.57,$ $p=0.27^{NS}$
Horner's syndrome	1(3.33%)	1(3.33%)	2(6.66%)	
Vascular injury	0	0	0	
Total	30(100%)	30(100%)	30(100%)	

Discussion:

Regional nerve blocks along with local anaesthetics provide good operative conditions with complete muscle relaxation for upper limb surgeries. Supraclavicular block is performed at the distal trunk and proximal divisions and hence provides rapid onset, predictable and dense anaesthesia along with high success rate which makes it ideal for surgeries of the upper limb [2, 3]. Many local anaesthetics have been used for brachial plexus block but all are associated with drawbacks such as short duration of action and toxicity. Ropivacaine is also a long acting local anaesthetic and has higher threshold for cardiotoxicity and CNS toxicity [11]. The minimal effective concentration of Ropivacaine was found to be 0.5%, and the benefit of increasing its concentration to 0.75% or 1% did not have significant difference in the onset of sensory and motor block or prolonged duration of analgesia [12]. Liao *et al.* [13] found that 30 ml of 0.5% Ropivacaine was adequate volume required for US-guided retrograde infraclavicular brachial plexus block. In the present study 30 ml of 0.5% Ropivacaine was used based on the previous evidence regarding optimal dose of the drug that are reportedly safe to use [14,15].

The major disadvantage of using local anaesthetic alone is that it does not prolong the duration of post operative analgesia [5]. The search for ideal adjuvant to local anaesthetics to prolong the duration of analgesia lead us to compare and evaluate Dexmedetomidine and Clonidine added as an adjuvant to Ropivacaine.

Clonidine is a centrally acting selective partial alpha 2 -adrenergic agonist which has been found to extend the duration of nerve block when added as an adjuvant to local anaesthetics. A plethora of studies have confirmed the efficacy of clonidine as a local anaesthetic adjuvant in peripheral nerve blocks [16]. About 0.5 µg /kg was the minimum effective dose required to prolong the duration of analgesia [17]. Most studies used between 100-150 µg, with doses up to 150 µg have significant analgesic effect and minimum side effects [18]. Taking into consideration the outcomes of previous studies 150 µg dose of Clonidine was taken in our study.

Dexmedetomidine is a newer α -2-adrenoreceptor agonist currently in focus for its sedative, anxiolytic and analgesic properties. It showed that Dexmedetomidine enhances duration of bupivacaine anaesthesia and analgesia of sciatic

nerve block without any damage to the nerve [19]. Dexmedetomidine 2µg/kg was found to have fast onset of sensory and motor block with good post operative analgesia [20, 21]. Joseph *et al.* found that a dose of 100 µg provided prolonged duration of analgesia as compared to 30 µg and 50 µg, without much significant side effects [22]. Hence in our study, 100 µg dose of Dexmedetomidine was taken.

For a drug, it is to be produced intended clinical effects; it must be firstly reached to its target site of action in the body with an effective concentration. Ghoshmaulik *et al.* [23] and Bedi *et al.* [24] found that perineurally injected clonidine prolonged the duration of action of the block as compared to subcutaneously injected clonidine. Kathuria *et al.* [25] concluded that Dexmedetomidine given perineurally has faster onset and prolonged duration of analgesia as compared to intravenous administration. Hence, we chose to give the adjuvant through this route. None of the blocks failed as all the blocks were performed by an experienced anaesthetist with a minimum of 3 years experience in performing blocks with nerve locator [26].

Gopal *et al.* [27] found that the onset of sensory block was 3.58 ± 0.61 min in Dexmedetomidine group, 6.88 ± 0.59 min in Clonidine group and 9.95 ± 2.8 min in Levobupivacaine group. Similar results were obtained by Ammar *et al.* [28] who found statistically significant shorter time to onset of sensory block in Dexmedetomidine group as compared to plain bupivacaine in infraclavicular block. In our study, we found similar results were in Group DX the onset of sensory block was fastest followed by Group CD and followed by Group CL. Dixit *et al.* [29] found that the onset of

complete sensory block was significantly faster in group Dexmedetomidine group compared to group Levobupivacaine alone. Karthik *et al.* [30] found that the onset of complete sensory block was faster in Dexmedetomidine group as compared to clonidine group. Our results were comparable to the results of their study.

Swami *et al.* [31] and Palsule *et al.* [32] found that the onset of motor block was faster in Dexmedetomidine group and Clonidine group as compared to bupivacaine alone group. We also found that the onset of motor block was faster in group DX and group CD followed by group CL. Tandon *et al.* [33] found that onset of complete motor block was rapid in Dexmedetomidine group as compared to Clonidine and Lignocaine alone group.

Kirubahar *et al.* [34] in their study concluded that onset of complete motor block was significantly faster in Dexmedetomidine group as compared to clonidine group. Our result was in concordance with their study. Chaudhary *et al.* [35] in their study found that duration of motor block was maximum with Dexmedetomidine group followed by clonidine group followed by bupivacaine alone group. We found similar results in our study.

Meena *et al.* [36] observed that the pulse rate and systolic and diastolic pressure were significantly decreased in the BD (Bupivacaine + Dexmedetomidine) group after 15 minutes when compared to (BS) group. We found that there was a significant fall in MAP and pulse rate in Dexmedetomidine and Clonidine groups 10 min after the injection as compared to Ropivacaine alone group. Though there was a significant fall in MAP and pulse rate but no patient had MAP

< 60 mm Hg and the pulse rate did not fall below 60 bpm. So, we can label the patients' haemodynamically stable. More *et al.* [37] used these two drugs in block and found that the respiratory rate was comparable among the groups throughout the study period which was similar to the findings of our study.

Palsule *et al.* [32] and Karthik *et al.* [30] observed that Dexmedetomidine lead to arousal sedative effect. In our study, from 15 min till 240 min after the block, patients belonging to Group DX were having significantly more sedation compared to patients in CD Group but none of the patients had sedation score more than 4 and was easily arousal. Tripathi *et al.* [38], Tandon *et al.* [33] and Chaudhary *et al.* [35] who did a comparative study of Clonidine and Dexmedetomidine as an adjuvant to Bupivacaine found that the duration of analgesia was significantly prolonged in group Dexmedetomidine and group Clonidine as compared to local anaesthetic alone while among the two groups Dexmedetomidine had significantly longer duration of analgesia compared to Clonidine group. In our study also duration of analgesia was significantly prolonged in Dexmedetomidine group followed by clonidine group followed by Ropivacaine alone group.

The several suggested mechanism of action which explain the analgesic effect of these drugs are local vasoconstriction leading to a delay of the absorption of the local anaesthetic, [39] reduction in the peak amplitude of compound action potential and thus blockage of nerve conduction [40], suppression of release of proinflammatory mediator [41] an increase in anti-inflammatory cytokines through an α -2-adrenoceptor mediated mechanism [42].

Pneumothorax and Horner's syndrome which are supraclavicular approach related complications developed in few patients across the groups but no statistically significant difference was found among the three groups. These results were similar to results found by Das *et al.* [43]. In our patients, Pneumothorax was detected on x-ray in the post operative period which was minimum and did not require any specific treatment so we have not omitted these patients from our study. Pneumothorax is the commonest complication of when supraclavicular approach for brachial plexus block is used compared to other approaches [44]. The prevalence of supraclavicular block ranges from 0.5 to 6% and it diminishes with experience. The reason is the anatomical position of the apex which is just medial and posterior to the brachial plexus and behind the first rib [44].

From the above findings, it is suggested that Dexmedetomidine can be routinely used as an adjuvant to local anaesthetic for supraclavicular block. If injection Dexmedetomidine is not available, then injection Clonidine can be used as adjuvant to local anaesthetic.

Limitation of our study is that ultrasound guidance for the peripheral nerve location could have helped us to reduce the dosages and volumes of local anaesthetic and complications related to the supraclavicular block. Systemic absorption of the study drugs was not studied by giving either injection Clonidine and injection Dexmedetomidine intravenously in the Control Group.

Conclusion:

To conclude, in our study we found that Dexmedetomidine and Clonidine when added to Ropivacaine for supraclavicular brachial plexus blocks shorten the onset times for sensory and

motor blocks and prolong the duration of motor block and duration of analgesia. Both Clonidine and Dexmedetomidine have the added advantage of conscious sedation, hemodynamic stability, and minimal side effects which makes them a

potential adjuvant for nerve blocks. From our study we can say that Dexmedetomidine is a better alternate to clonidine as an adjuvant to local anaesthetic agent in supraclavicular brachial plexus blocks.

References

- Liu SS, Strodbeck WM, Richman JM, Wu CL. A comparison of regional versus general anesthesia for ambulatory anesthesia: a meta-analysis of randomized controlled trials: *Anesth Analg* 2005; 101(6): 1634-1642.
- Russon K, Pickworth T, Griffiths H. Upper limb blocks. *Anaesthesia* 2010; 65(1): 48-56.
- D'Souza RS, Johnson RL. Supraclavicular Block. In: StatPearls [Internet]. Treasure Island (FL): StatPearls Publishing; 2019 [cited 2019 Mar 20].
- Kuthiala G, Chaudhary G. Ropivacaine: A review of its pharmacology and clinical use. *Indian J Anaesth* 2011; 55(2):104-110.
- Raizada N, Chandralekha, Jain PC, Kumar A. Does compounding and increase in concentration of local anaesthetic agents increase the success rate of brachial plexus block? *Indian J Anaesth* 2002; 46(3): 193-196.
- Swain A, Nag DS, Sahu S, Samaddar DP. Adjuvants to local anesthetics: Current understanding and future trends. *World J Clin Cases* 2017; 5(8):307-323.
- Sahni N, Panda NB, Jain K, Batra YK, Dhillon MS, Jagannath P. Comparison of different routes of administration of clonidine for analgesia following anterior cruciate ligament repair. *J Anaesthesiol Clin Pharmacol* 2015; 31(4):491-495.
- Pöpping DM, Elia N, Marret E, Wenk M, Tramèr MR. Clonidine as an adjuvant to local anesthetics for peripheral nerve and plexus blocks: a meta-analysis of randomized trials. *Anesthesiology* 2009; 111(2):406-15.
- Grewal A. Dexmedetomidine: New avenues. *J Anaesthesiol Clin Pharmacol* 2011; 27(3): 297-302.
- Kundra P, Rajan PS. Alpha 2 agonists in regional anaesthesia practice: Efficient yet safe? *Indian J Anaesth* 2014; 58(6):681-683.
- Spivey WH, McNamara RM, MacKenzie R Bhat S, Burdick WP. A clinical comparison of lidocaine and bupivacaine. *Ann Emerg Med* 1987; 16(7):752-757.
- Venkatesh RR, Kumar P, Trissur RR, George SK. A randomized controlled study of 0.5% bupivacaine, 0.5% ropivacaine and 0.75% ropivacaine for supraclavicular brachial plexus block. *J Clin Diagn Res* 2016; 10(12):9-12.
- Liao J, Zhang X. Optimal volume of ropivacaine for ultrasound-guided retrograde infraclavicular brachial plexus block: 8AP2-2. *Euro J Anaesthesiol* 2011; 28:111.
- Casati A, Fanelli G, Aldegheri G, Berti M, Colnaghi E, Cedrati V, et al. Interscalene brachial plexus anaesthesia with 0.5%, 0.75% or 1% ropivacaine: a double-blind comparison with 2% mepivacaine. *Br J Anaesth* 1999; 83(6):872-875.
- Modak S, Basantwani S. Comparative study of 0.5% ropivacaine and 0.5% bupivacaine for brachial plexus block by supraclavicular approach for upper limb surgeries. *Int J Bas Clin Pharmacol* 2017; 5(4):1205-1209.
- Murphy DB, McCartney CJ, Chan VW. Novel analgesic adjuncts for brachial plexus block: A systematic review. *Anesth Analg* 2000; 90:1122-1128
- Singelyn FJ, Gouverneur J-M, Robert A. A minimum dose of clonidine added to mepivacaine prolongs the duration of anesthesia and analgesia after axillary brachial plexus block. *Anesth Analg* 1996; 83(5):1046.
- McCartney CJL, Duggan E, Apatu E. Should we add clonidine to local anesthetic for peripheral nerve blockade? a qualitative systematic review of the literature. *Reg Anesth Pain Med* 2007; 32(4):330-8.
- Brummett CM, Norat MA, Palmisano JM, Lydic R. Perineural administration of dexmedetomidine in combination with bupivacaine enhances sensory and motor blockade in sciatic nerve block without inducing neurotoxicity in rat. *Anesthesiology* 2008; 109(3): 502-511.

20. Nallam SR, Chiruvella S, Karanam S. Supraclavicular brachial plexus block: Comparison of varying doses of dexmedetomidine combined with levobupivacaine: A double-blind randomised trial. *Indian J Anaesth* 2017; 61: 256-261
21. Kumari I, Gehlot RK, Verma R. Comparison of two different doses of dexmedetomidine added to ropivacaine in patients posted for upper limb surgery under supraclavicular brachial plexus block. *Anaesth Pain Inten Care* 2017;21(2): 141-146.
22. Joseph DEJ, Vasukinathan DA, Dhanalakshmi DB. Comparison of three different doses of dexmedetomidine as adjuvant to bupivacaine in supraclavicular brachial plexus block for upper limb orthopaedic surgeries. *Int J Sci Res* 2017; 6(12):23-25
23. Ghoshmaulik S, Bisui B, Saha D Swaika S, Ghosh AK. Clonidine as an adjuvant in axillary brachial plexus block for below elbow orthopedic surgeries: A comparison between local and systemic administration. *Anesth Essays Res* 2012;6(2):184-188.
24. Bedi V, Petkar J, Dindor BK, Narang A, Tungaria H, Petkar KS. Perineural versus intravenous clonidine as an adjuvant to Bupivacaine in supraclavicular brachial plexus block. *Egypt J Anaesth* 2017; 33(3): 257-261.
25. Kathuria S, Gupta S, Dhawan I. Dexmedetomidine as an adjuvant to ropivacaine in supraclavicular brachial plexus block. *Saudi J Anaesth* 2015; 9(2):148-154.
26. Bhattarai R, Paudel B, Regmi G, Das C. Outcome of brachial plexus blocks with nerve stimulator and paresthesia technique. *Ann Int Med Dent Res* 2017; 3(2):35-37.
27. Gopal K, Mitra S, Verma AP, Agrawal M, Singh RP, Ahmad S. A comparative study between levobupivacaine with dexmedetomidine versus levobupivacaine with clonidine in ultrasound guided supraclavicular brachial plexus block for upper limb surgeries: a randomized double blind placebo controlled study. *Int J Contemp Med Res* 2018; 5(1): 6-11.
28. Ammar AS, Mahmoud KM. Ultrasound-guided single injection infraclavicular brachial plexus block using bupivacaine alone or combined with dexmedetomidine for pain control in upper limb surgery: A prospective randomized controlled trial. *Saudi J Anaesth* 2012; 6(2):109-114.
29. Dixit A, Singhal S, Neema C, Sanwatsarkar S, Bhatia M. An evaluation of the addition of Dexmedetomidine to Levobupivacaine for supraclavicular brachial plexus block in upper limb orthopaedic surgeries. *Asian Pac J Health Sci* 2015; 2(2):148-153.
30. Karthik GS, Sudheer R, Sahajananda H, S Rangalakshmi, Roshan K. Dexmedetomidine and clonidine as adjuvants to levobupivacaine in supraclavicular brachial plexus block: a comparative randomised prospective controlled study. *J Evo Med Dent Sci* 2015; 4(19): 3207-3221.
31. Swami SS, Keniya VM, Ladi SD, Rao R. Comparison of dexmedetomidine and clonidine (α_2 agonist drugs) as an adjuvant to local anaesthesia in supraclavicular brachial plexus block: A randomised double-blind prospective study. *Indian J Anaesth* 2012; 56(3):243-249.
32. Palsule VS, Shah AP, Kanzariya HH. Dexmedetomidine in supraclavicular block: Effects on quality of block and analgesia. *Indian J Pain* 2017; 31(1): 28-34.
33. Tandon N, Gupta M, Agrawal J, Mathur A, Gupta S, Yadav S *et al.* A comparative clinical study to evaluate the efficacy of levobupivacaine with clonidine and levobupivacaine with dexmedetomidine in supraclavicular brachial plexus block. *J Evo Med Dent Sci* 2016; 5(19): 925-929.
34. Kirubahar R, Sundari B, Kanna V, Murugadoss K. Comparison of clonidine and dexmedetomidine as an adjuvant to bupivacaine in supraclavicular brachial plexus block for upper limb orthopedic procedures. *Int J Res Med Sci* 2016; 4(4):1172-1176.
35. Chaudhary UK, Danesh A, Mahajan M, Sudarshan K, Verma V, Awasthi B. Comparison of effects of dexmedetomidine and clonidine as adjuvant to bupivacaine 0.25% in ultrasound guided supraclavicular brachial plexus block. *Int J Res Med Sci* 2017; 5(10): 4512-4518.
36. Meena R, Loha S, Pandey AR, Meena K, Paswan AK, Chaudhary L, *et al.* Dexmedetomidine as an adjuvant to bupivacaine in supraclavicular brachial plexus block. *J Anesth Clin Res* 2016; 7: 674
37. More P, Basavaraja, Laheri V. A comparison of dexmedetomidine and clonidine as an adjuvant to local anaesthesia in supraclavicular brachial plexus block for upper limb surgeries. *J Med Res* 2015; 1(5):142-147.
38. Tripathi A, Sharma K, Somvanshi M, Samal R. A comparative study of clonidine and dexmedetomidine as an adjunct to bupivacaine in supraclavicular brachial plexus block. *J Anaesthesiol Clin Pharmacol* 2016; 32(3):344.

-
39. Yabuki A, Higuchi H, Yoshitomi T, Tomoyasu Y, Ishii-Maruhama M, Maeda S, *et al.* Locally Injected Dexmedetomidine Induces vasoconstriction via peripheral α -2A adrenoceptor subtype in guinea pigs. *Reg Anesth Pain Med* 2014; 39(2):133.
40. Kosugi T, Mizuta K, Fujita T, Nakashima M, Kumamoto E. High concentrations of Dexmedetomidine inhibit compound action potentials in frog sciatic nerves without α 2 adrenoceptor activation. *Br J Pharmacol* 2010; 160(7):1662-1676.
41. Kawasaki T, Kawasaki C, Ueki M, Hamada K, Habe K, Sata T. Dexmedetomidine suppresses proinflammatory mediator production in human whole blood in vitro. *J Trauma Acute Care Surg* 2013; 74(5):1370.
42. Yoshitomi T, Kohjitani A, Maeda S, Higuchi H, Shimada M, Miyawaki T. Dexmedetomidine enhances the local anesthetic action of lidocaine via an α -2A adrenoceptor. *Anesth Analg* 2008;107(1):96
43. Das A, Majumdar S, Halder S, Chattopadhyay S, Pal S, Kundu R, *et al.* Effect of dexmedetomidine as adjuvant in ropivacaine-induced supraclavicular brachial plexus block: A prospective, double-blinded and randomized controlled study. *Saudi J Anaesth* 2014; 8(1):72-7.
44. Kumari A, Gupta R, Bhardwaj A, Madan D. delayed pneumothorax after supraclavicular block. *J Anaesthesiol Clin Pharmacol* 2011; 27(1): 121-122.
-

**Author for Correspondence: Dr. Amol Singam, Dept of Anaesthesiology, AVBRH affiliated to Jawaharlal Nehru Medical College, Sawangi, Wardha-442001 Email: dramolsingam@gmail.com. Cell: +91-9422538005*